

# ULTRASONOGRAPHY STUDY: SUBCUTANEOUS FAT REDUCTION

## CHANGES IN SUBCUTANEOUS ABDOMINAL FAT THICKNESS FOLLOWING HIGH-INTENSITY FOCUSED ELECTRO-MAGNETIC (HIFEM®) FIELD TREATMENTS: A MULTI CENTER ULTRASOUND STUDY.

Bruce Katz M.D.<sup>1</sup>, Robert Bard M.D.<sup>2</sup>, Richard Goldfarb M.D.<sup>3</sup>,  
Aaron Shiloh M.D.<sup>4</sup>, Dilyana Kenolova M.D.<sup>5</sup>

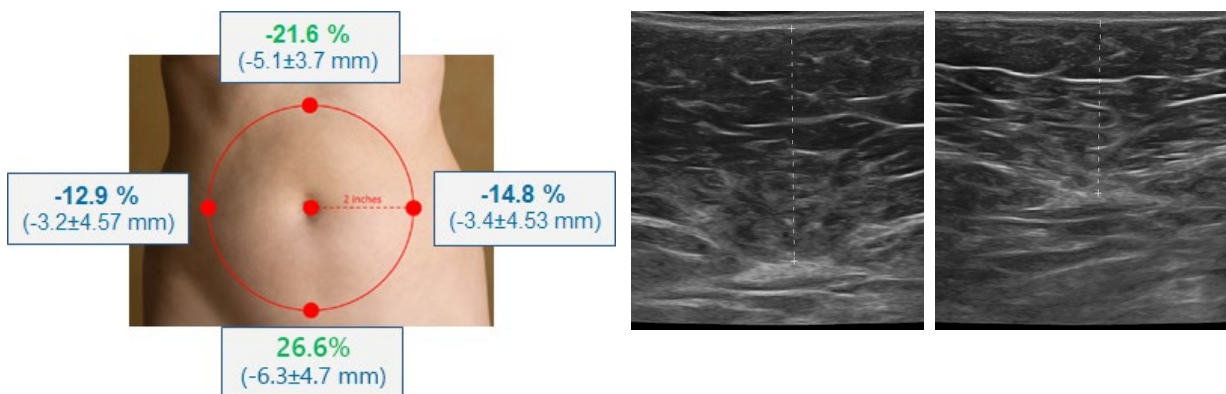
1. Juva Skin and Laser Center, Manhattan NY, USA; 2 Bard Cancer Diagnostics, Manhattan, NY, USA; 3. Center for SmartLipo & Plastic Surgery, Langhorne PA, USA; 4. Shiloh Vein and Aesthetic Institute, Philadelphia PA, USA; 5. Dermasense Dermatology Clinic, Burgas, Bulgaria.

Presented at the Annual Meeting of the American Society for Laser Medicine and Surgery, 2018 Dallas, TX.

---

### HIGHLIGHTS

- **33 patients** received four 30-minute treatments and were evaluated 1 month post application.
- **Ultrasonography** calculated fat thickness in multiple measurement points **covering the whole abdomen**.
- On average **19.0 % (4.4 mm)** reduction of fat was observed. The most significant **reduction in fat (26.6 %)** was observed **subumbilicaly**.
- **High consistency** with **0 non-responders**; 21 out of 33 patients had greater than 15 % fat reduction.
- **91 % satisfaction** with treatment results.



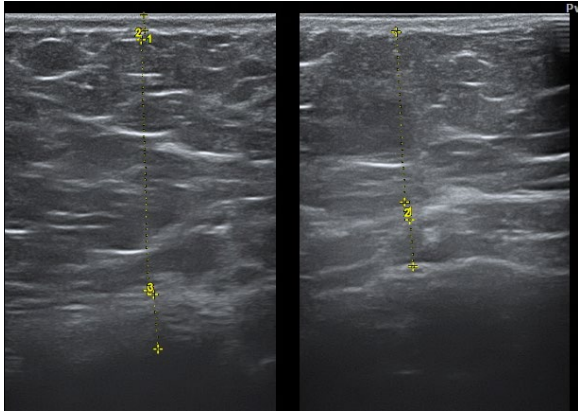
Ultrasound measurements revealed that fat was reduced significantly ( $p < 0.05$ ) in all abdominal areas, with the highest change seen in epi- and sub-umbilical regions.

# RESULTS

## Patient 3: 24 years old female

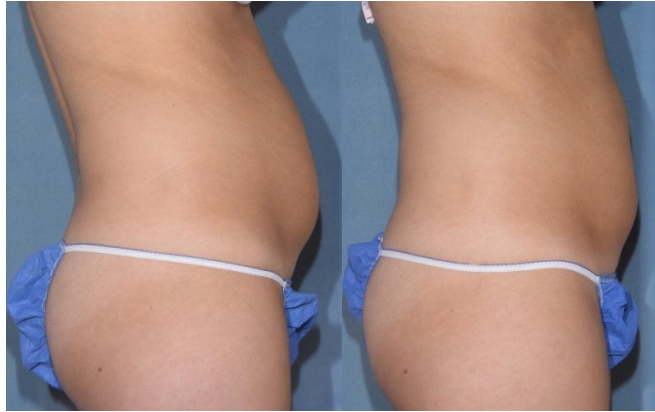BASELINE

1 MONTH FU



BASELINE

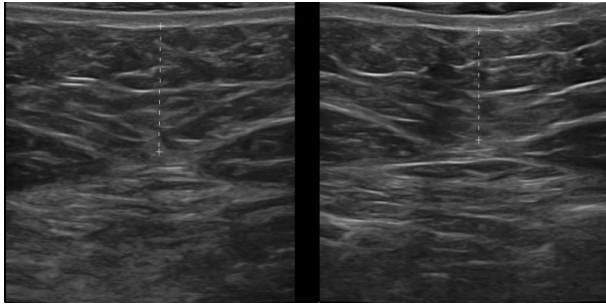
1 MONTH FU



## Patient 15: 47 years old female

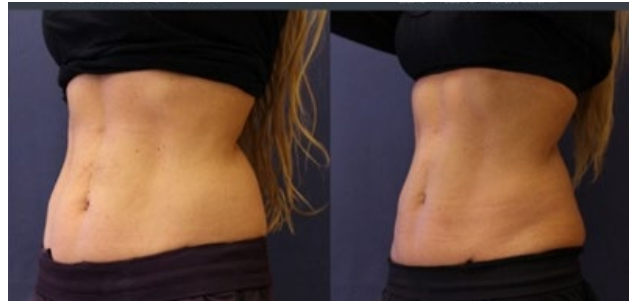BASELINE

1 MONTH FU



BASELINE

1 MONTH FU

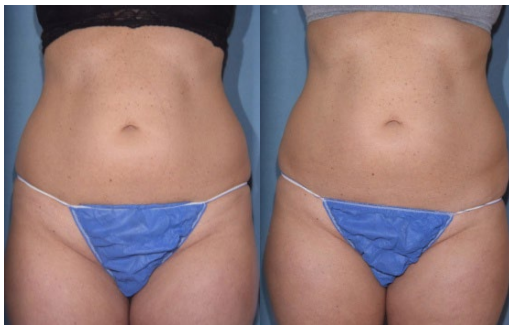

## Patient 6: 44 years old female

### 2D Photography

BASELINE

1 MONTH FU



### 3D Photography

BASELINE

1 MONTH FU

